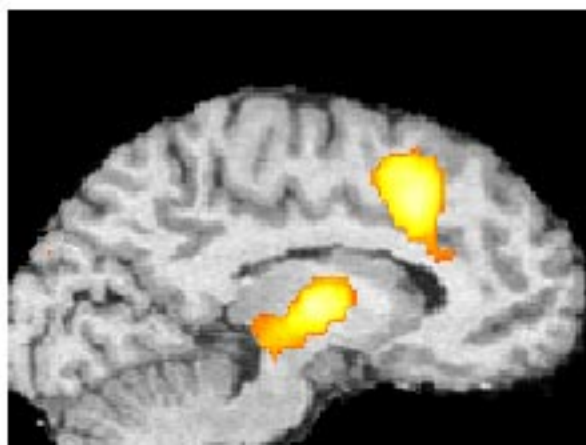
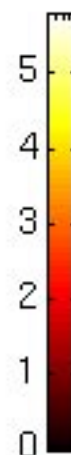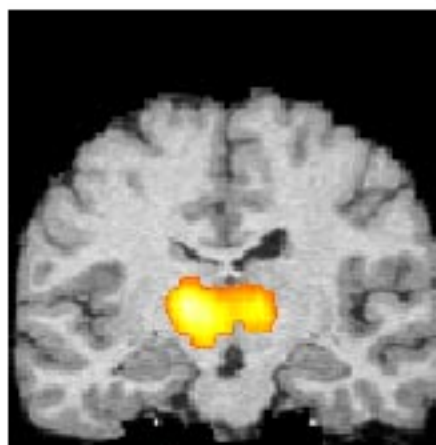


saggital



coronal



transverse

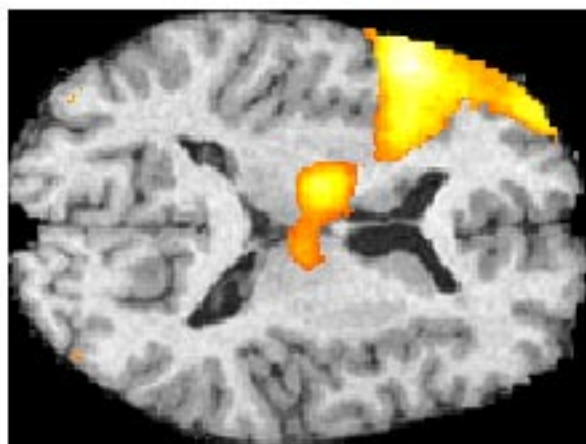


Figure 4